

# A Temporoparietal and Prefrontal Network for Retrieving the Spatial Context of Lifelike Events

Neil Burgess,\* Eleanor A. Maguire,† Hugo J. Spiers,\* and John O'Keefe\*

\**Institute of Cognitive Neuroscience and Department of Anatomy, University College London, 17 Queen Square, London WC1N 3AR, United Kingdom; and* †*Wellcome Department of Cognitive Neurology, Institute of Neurology, University College London, 12 Queen Square, London WC1N 3BG, United Kingdom*

Received November 2, 2000; published online May 30, 2001

**Virtual reality (VR) and event-related functional magnetic resonance imaging were used to study memory for the spatial context of controlled but lifelike events. Subjects received a set of objects from two different people in two different places within a VR environment. Memory for the objects, and for where and from whom they were received was tested by putting the subject back into a place in the company of a person and giving a paired forced choice of objects. In four conditions objects had to be chosen according to different criteria: which was received in that place, which was received from that person, which object was recognized, and which object was widest. Event-related functional magnetic resonance imaging was performed during testing to identify areas involved in retrieval of the spatial context of an event. A network of areas was identified consisting of a temporoparietal pathway running between the precuneus and parahippocampi via retrosplenial cortex and the parieto-occipital sulcus, left hippocampus, bilateral posterior parietal, dorsolateral, ventrolateral and anterior prefrontal cortices, and the anterior cingulate. Of these areas the parahippocampal, right posterior parietal, and posteriodorsal medial parietal areas were specifically involved in retrieval of spatial context compared to retrieval of nonspatial context. The posterior activations are consistent with a model of long-term storage of allocentric representations in medial temporal regions with translation to body-centered and head-centered representations computed in right posterior parietal cortex and buffered in the temporoparietal pathway so as to provide an imageable representation in the precuneus. Prefrontal activations are consistent with strategic retrieval processes, including those required to overcome the interference between the highly similar events.** © 2001 Academic Press

referred to as “episodic” (Tulving, 1983) and is crucially dependent on the medial temporal lobes (Scoville and Milner, 1957; Aggleton and Brown, 1999; Vargha-Khadem *et al.*, 1997; O'Keefe and Nadel, 1978). An event may be defined as a temporally localized change in the state of the world (e.g., “it started to rain,” or “she called him”), although our memory for the occurrence of the event often includes more than just those changes. It is possible to distinguish between three types of information that may be stored in the memory for a real-world event: first, there is information corresponding to the content of the event itself, i.e., to the change in the world that forms the event; second, information corresponding to the ongoing external context of the event, such as where and when it occurred, who was involved, etc.; third, information corresponding to ongoing internal states (e.g., emotional) of the subject at the time of the event. In this paper we concern ourselves with the first two types of information, the content and external context of events, and focus specifically on the spatial context.

It has been argued that, in some circumstances, memory for the content and the context of events may dissociate. Content of events can be recognized in the absence of knowledge regarding the context of the event, perhaps via an unattributable feeling of familiarity or “knowing.” This type of recognition memory has been contrasted with the recall of specific context-dependent episodic information, or “remembering” (Gardiner and Java, 1993; Tulving, 1993; Knowlton and Squire, 1995). Lesion data from humans and animals have implicated the hippocampus in the recall of context-dependent episodic information but not in content-memory such as object recognition (O'Keefe and Nadel, 1978; Zhu *et al.*, 1996; Murray and Mishkin, 1998; Baxendale *et al.*, 1997; Vargha-Khadem *et al.*, 1997; Wan *et al.*, 1999; Aggleton and Brown, 1999; although see Manns and Squire, 1999; Zola *et al.*, 2000, for an alternative point of view). This can be interpreted as a distinction between recognition and recall, although the difference between these two processes is

## INTRODUCTION

Memory for the events we experience as we move around our environment is fundamental to normal functioning in daily life. This type of memory is often

not always clear-cut. Here we use a paired forced choice recognition paradigm in all memory conditions; however, some conditions clearly involve recall, e.g., making the choice of which object was received in a given place, see below.

As well as its undoubted role in episodic memory, there is also a wide range of research from animals implicating the hippocampal formation in large-scale spatial memory and navigation (O'Keefe and Nadel, 1978; Morris *et al.*, 1982). In humans, neuropsychological studies have implicated the right medial temporal lobes in spatial tasks (Smith and Milner, 1989; Nunn *et al.*, 1999; Pigott and Milner, 1993; Baxendale *et al.*, 1998), including the hippocampus and parahippocampus (Abrahams *et al.*, 1999; Bohbot *et al.*, 1998). Functional neuroimaging evidence (Maguire *et al.*, 1998; Grön *et al.*, 2000) points to a role for the right hippocampus in the performance of spatial navigation, paralleling that in animals. The involvement of the left human hippocampus during real-world spatial memory tests has also been observed (Maguire *et al.*, 1998; Grön *et al.*, 2000; Maguire *et al.*, 1996), but its contribution appears distinctly different to the right, possibly relating to more general aspects of episodic memory (Maguire *et al.*, 1998; Grön *et al.*, 2000). The posterior parahippocampus has also been implicated in topographical either alone or in conjunction with the hippocampus for object location memory (Abrahams *et al.*, 1999; Ghaem *et al.*, 1997) and in memory for the locations of objects (Johnsrude *et al.*, 1999; Maguire *et al.*, 1998b). It has been suggested that the use of spatial context in episodic recollection might explain how the role of the hippocampus in spatial memory in rats has evolved into a role in more general episodic recall in humans (O'Keefe and Nadel, 1978).

A related line of argument holds that the complementary representations of location found in hippocampal and parietal regions naturally predispose them to complementary roles in memory (Goodale and Milner, 1992; Milner *et al.*, 1999; Burgess *et al.*, 1999). Specifically, the allocentric (world-centered) representations found in and around the hippocampus (O'Keefe and Nadel, 1978) and presubiculum (Taube, 1998) are suitable for long term storage of spatial information as the animal will have moved before recall. Conversely, the egocentric representations found in the parietal cortex (Hyvarinen and Poranen, 1974; Mountcastle *et al.*, 1975) are suitable for supporting action, short-term memory, and imagery. Posterior parietal areas (specifically area 7a) appear to support the necessary translation of spatial information between allocentric and body-centred reference frames (Snyder *et al.*, 1998) and between the various egocentric reference frames (Andersen *et al.*, 1985). This position is consistent with the occurrence of hemispatial neglect in imagery following right parietal or frontal damage (Bisiach and Luzzatti, 1978; Guariglia *et al.*, 1993). These patients

appear to have an intact viewpoint-independent long-term representation of an entire familiar piazza, but right parietal or frontal damage has impaired their ability to construct a viewpoint dependent representation in imagery (see also (Baddeley and Leiber, 1980)). Such a spatial memory system would be expected to include the parahippocampus in representing the spatial information in visual scenes (Epstein and Kanwisher, 1998; Aguirre *et al.*, 1996; Bohbot *et al.*, 1998; Maguire *et al.*, 1997; Maguire *et al.*, 1998b) and the posterior cingulate and retrosplenial cortices, which have also been associated with topographical memory (Takahashi *et al.*, 1997; Alsaadi *et al.*, 2000; Cooper and Mizumori, 1999).

Functional neuroimaging of memory for the spatial context of an event has previously been used to investigate the neural basis of episodic memory, using words presented in different parts of a computer screen (Nyberg *et al.*, 1996; Henson *et al.*, 1999; Rugg *et al.*, 1999; Kohler *et al.*, 1998). Interestingly, these studies have tended to show prefrontal rather than medial temporal activation. In a conjunctive analysis of four studies LePage *et al.* (2000) identified six prefrontal areas in the anterior cingulate, bilateral dorsolateral, and anterior and right ventrolateral prefrontal, implicated in episodic memory. In addition, the precuneus has been associated with imagery for the products of retrieval (Fletcher *et al.*, 1995).

More generally it is noticeable that functional neuroimaging during retrieval of conventional laboratory stimuli such as lists of words, pictures, or word pairs have been more successful in activating prefrontal areas than medial temporal ones (Tulving *et al.*, 1994; Ungerleider, 1995; Fletcher *et al.*, 1997). Midline areas such as the anterior cingulate (Buckner *et al.*, 1996; Nyberg *et al.*, 1996; Heun *et al.*, 1999) and posterior cingulate or retrosplenial cortex (Andreasen *et al.*, 1995; Krause *et al.*, 1999; Desgranges *et al.*, 1998; Wiggs *et al.*, 1999; Grasby *et al.*, 1993) are also typically activated in these studies. The number of studies showing retrieval-related medial temporal activations has increased recently, for example, Eldridge *et al.* (2000) found hippocampal activation associated with "remembering" versus "knowing" that a word had been previously presented. However, these studies remain a fraction of the number of studies that do not show medial temporal activation; see e.g., Schacter and Wagner (1999a), including studies using similar paradigms to those that do, e.g., Henson *et al.* (1999b).

By contrast, recent studies of autobiographical memory have implicated the medial temporal lobes in episodic retrieval on the left (Maguire and Mummery, 1999; Maguire *et al.*, 2000) or on the right (Fink *et al.*, 1996). These studies use autobiographical interviews (see, e.g., Kopelman *et al.*, 1989) or interviews of family members, aimed at finding out the details of events actually experienced by the subject so that they can be

tested on their memory for them. Here the material to be remembered, although accessed in the form of verbal descriptions, are drawn from real life events. Thus it is possible that the feature of episodic retrieval concerning the medial temporal lobes relates to recovery of the rich context associated with an event, e.g., the people and places involved. However, obtaining large numbers of such stimuli and controlling for differences between the salience and type of events, differences between subjects, and interference subsequent to encoding (e.g., during the interview or in conversation with family members) as well as gauging the accuracy of recall can all be difficult. Perhaps because of some of these problems, studies using autobiographical stimuli have so far not attempted to distinguish between specific aspects of retrieval and in particular the retrieval of spatial context.

In this paper we present a virtual reality (VR) paradigm that provides a controlled way of testing memory for different aspects of a lifelike event and its context. Each event consisted of getting an object from one of two different people in one of two different places while the subject followed a route through a virtual town. The object received identified the event while the event's context included the person and place involved. We focus on memory for the context of an event and, most specifically, where it happened. Testing used the same paired forced-choice recognition paradigm for all conditions: Two objects and a person were presented in a place and four types of question were indicated by a single word below objects. (See Fig. 1.) There were three memory conditions: "place"—which object did you receive in this place? "person"—which object did you receive from this person? "object"—which object did you receive? The fourth condition was purely perceptual: "width"—which object is widest? For place questions the choice was between an object received in the current place and one received elsewhere. This tested memory for spatial context. For person questions the choice was between an object received from the current person and one received from a different person. This served as a control for nonspatial context-dependent memory. For object questions the choice was between an object that had been received and a novel object of similar appearance. This controlled for context independent memory. For width questions the choice was between two of the received objects. This controlled for memory.

Event-related functional magnetic resonance imaging (efMRI) was performed while subjects answered the questions. Although navigating through and out of the places where questions occurred, participants were static while a question was presented and during a 4-s wait until two buttons appeared onscreen to indicate that a left-right keypad response should be made to indicate one of the objects. The question types were pseudorandomly interleaved. Thus all conditions in-

involved presentation of the same visual scenes, performance of the same responses, and the same behaviour and expectations before and after each question. An event-related analysis was performed on the fMRI data, with events associated with the pause between presentation and response of correctly answered questions. See Materials and Methods.

## MATERIALS AND METHODS

### *Virtual Town*

A first-person perspective virtual reality town was created by modifying a commercial PC video game (Duke Nukem 3D, 3D Realms Entertainment, Apogee Software Ltd., Garland, TX), using the editor provided (Build, Ken Silverman, 3D Realms Entertainment). The town consisted of several buildings and roads through which subjects could move (similar to that used in a previous study (Maguire *et al.*, 1998)); see Fig. 1. Subjects moved through the town using four keys corresponding to forward, reverse, left, and right. Prior to entering the scanner, a 17-inch PC monitor was used to present the stimuli. Subjects explored the town until they felt confident they could find their way around it (range: 20–40 min). They then practised following a route of arrows, meeting a person on the route and getting an object from them (pressing a fifth button when 2–5 m away from a person causes an object to appear in front of the person, approaching close to the object causes it to disappear again—see Fig. 1). Subjects also practised receiving four objects (using different people and places than those used during the experiment proper) and also practised answering one of each type of paired forced choice question regarding the objects collected. They were told to simply pay attention to the events as they would be tested on their memory for the object, where they got it, and whom they got it from. They were told that the person should be ignored during a place question and the place should be ignored during a person question as these would be irrelevant. To screen for subjects that might use any elaborate verbal or visual mnemonic strategy, they were asked how they had answered the practice questions. If they answered "I just tried to remember what happened" or similar, they were told "good, that is what we want you to do." Anyone using an explicit strategy was told to simply "pay attention to the events" and "just try to remember what happened" during scanning. After scanning subjects were again debriefed to check whether any explicit strategy had been used. All participants entered into the efMRI analysis appeared to understand the instructions and none of them reported using an explicit mnemonic strategy.

### Procedure

Following practise, subjects entered the scanner. The town was displayed on a  $24 \times 16$ -cm screen appearing 30 cm above the eyes, subjects moved through the town by pressing four buttons on a keypad using their right hand and indicated left/right responses by pressing two buttons on a keypad using their left hand. Once in the scanner but prior to scanning, subjects followed the route of arrows and received 16 objects from two people in two places (these were the 16 episodic events). The objects, people, and places were all different from those used during practise but the route was the same. The places were two rooms in different buildings, the precise location of the people in the rooms and the direction from which they were approached varied. This, together with the rooms' rather similar décor meant that the place of an event was not simply synonymous with the visual scene when it occurred. Scanning was then performed while subjects performed 64 paired forced choice recognition tests corresponding to the four types of question regarding the 16 events. The four different types of question (conditions) were pseudorandomly interleaved such that each block of four contained one question from each condition. Each question occurred as follows: the subject found himself near one of the two places where he had received objects. He then approached the person present in that place and turned to face the nearest wall (this direction was indicated by an arrow). This procedure was used to ensure that the subjects' perception of place was supported by the process of getting there as well as by visual recognition. Two objects then appeared side by side on the wall, together with a word indicating the type of question to be answered (place, person, object, width). Four seconds later two buttons appeared on the wall to indicate that the subject should now make the left–right response to answer the question using the keypad. The subject then moved through the nearest doorway marked “next,” which triggered the presentation of the next question. Ethical permission for this study was provided by the joint medical committee of the National Hospital for Neurology and Neurosurgery and the Institute of Neurology. All participants gave written informed consent.

### Scanning Parameters and Data Analysis

Data were acquired using a 2 Tesla Magnetom VISION (Siemens, Erlangen, Germany) whole body MRI system equipped with a head volume coil. Contiguous multislice T2\*-weighted fMRI images were obtained (echo time (TE) = 40ms) with echoplanar imaging (EPI) using axial slice orientation. The volume acquired was the whole head (32 slices, each 3-mm thick, 3.3-s per volume). For each subject 400 volumes were acquired continuously in 21 min, while the subjects made their 64 responses. A structural MRI scan using

a standard three-dimensional T1-weighted sequence was also acquired. Image analysis was performed using SPM99 (Wellcome Department of Cognitive Neurology, London, UK). The T2\* images for each subject were preprocessed as follows: they were realigned (with each other) and coregistered with the structural scan. Temporal linear interpolation was used so that each volume could be considered as acquired simultaneously despite the sequential acquisition of slices. The EPI and structural images were spatially normalized to a standard template (Montreal Neurological Institute; Evans *et al.*, 1993) to produce images of  $3 \times 3 \times 3$ -mm voxels (EPI) and  $1.5 \times 1.5 \times 1.5$ -mm voxels (structural) in stereotactic space (Talairach and Tournoux, 1988). These images were then spatially smoothed with a Gaussian filter (6 mm FWHM). As part of the functional analysis (see below), the EPI images were temporally smoothed with a Gaussian (4 s FWHM), high-pass filtered, and scaled to give a grand mean signal of 100 across all voxels in all images to remove global effects. The maximum period of signal passed by the high pass filter was set to  $2*(3.3 + t)$ , where  $t$  is the maximum duration between events of a given type so as not to filter out event-related signal (maximum period across subjects has mean 306 s, standard deviation 37 s).

As subjects' responses were self-paced, their responses (left or right key presses) and the slice being acquired at that time were logged so that an event-related analysis (Friston *et al.*, 1998) could be performed. During the 4 s prior to a response we presume that the subject looked at the objects, read the word describing the question type, and decided on his response. For place and person questions the decision depends on memory for the appropriate aspect of the events associated with the objects, for object questions it depends on recognition of one of the objects, for width questions it depends on visual inspection of the objects. The MRI signal at a voxel corresponding to each condition was modelled as a vector of haemodynamic response functions time aligned to 1 vol acquisition (i.e., 3.3 s) prior to each correct response in that condition. Incorrect responses were not analyzed as these do not necessarily correspond to the appropriate mnemonic processing. The coefficients of these vectors forming the best fitting linear model were found using SPM99 (Wellcome Dept. of Cognitive Neurology, London, UK). Pairs of images of coefficients (referred to as 'parameter estimates' below) were combined by subtraction to form contrast images corresponding to the following hierarchical planned comparisons: place–width, place–object, place–person, person–width, person–object, object–width. We consider the areas showing significant differences in parameter estimates across the 13 participants (see below). For these areas we also consider the absolute values of the parameter estimates across the four conditions.

We assume that the size of a parameter estimate in a voxel reflects the size of the hemodynamic response to neural activity or 'activation' related to events in the corresponding condition. The significance of a comparison at each voxel was tested with a one-tailed one-sample *t* test of the value of the contrast being greater than zero (e.g., place-width > 0). Differences in predicted areas of interest (hippocampus, parahippocampus, cingulate, medial and posterior parietal, retrosplenial, fusiform gyrus, dorsolateral, ventrolateral, and anterior prefrontal cortices; see Introduction) were assessed as significant at the  $P < 0.001$  level uncorrected for multiple comparisons, and  $P < 0.05$  corrected for multiple comparisons in other areas. A minimum extent threshold of at least 3 voxels was also imposed.

Note that the event-related haemodynamic response reflected in a parameter estimate is relative to the baseline activity before and after the events. This study uses a very active baseline task of moving through the town looking for a person (before the event) and looking for the exit (after the event). The events themselves (answering a memory or control question) occur when the subject is static. As this is the same for all conditions it has no impact on the contrasts of parameter estimates. However, we would expect the absolute values of parameters to be negative in areas strongly activated by the baseline task. The absolute value of a parameter can be compared to the percentage signal change from baseline at the peak of the hemodynamic response to an event of a given type by multiplying by 2.84 (the peak height of the hemodynamic response function).

## RESULTS

### *Behavioural Data*

Subjects in sound physical and mental health were recruited from adverts placed in the departments of Psychology and Anatomy. Two thresholds were applied to subjects' performance: no more than 11 errors in the context-dependent memory questions combined (place and person, i.e., above chance at the 0.05 level) and no more than six errors in each individual condition (i.e., above chance at the 0.25 level). The data from 13 healthy right-handed male volunteers (mean age 27.2, standard deviation 1.0 years) exceeding these thresholds were entered into a random effects analysis, see Materials and Methods. Seven subjects failed to exceed these thresholds (mean and standard deviation of number of errors per condition were: place, 7.0, 1.6; person, 6.7, 3.0). Not all 13 subjects entered into the analysis answered all 16 questions in each condition during the scanning period (mean number of questions answered and standard error per type: 15.5 ± 0.3 place; 15.2 ± 0.2 person; 15.2 ± 0.2 object; 15.2 ± 0.2


width). The mean and standard error for the inter-event intervals were 22.5 and 0.6 s. There was no significant difference in performance between the two context-dependent questions: person (80%, S.E. 3%), place (79%, S.E. 2%). Performance on the object question was significantly better (88%, S.E. 2%). Answers to width questions were assumed correct given the participant's point of view.

### *efMRI Data*

The entire network activated by accessing the memory for spatial context can be seen by contrasting place with the (nonmemory) width condition. Areas of significant activation are shown in color in Fig. 2A and detailed in Table 1. Interestingly, this contrast reveals a well-circumscribed pattern of activation in all three areas mentioned in the Introduction. This includes the parietal and prefrontal areas implicated by neuroimaging of retrieval of conventional laboratory stimuli, and the medial temporal areas implicated in neuropsychological studies and in neuroimaging of retrieval of autobiographical stimuli. More specifically, these activations fall into four broad anatomical regions: (i) an almost continuous activation running between the precuneus and bilateral parahippocampal cortices via the parieto-occipital sulcus and retrosplenial cortices, extending into the hippocampus on the left; (ii) bilateral posterior parietal cortex; (iii) anterior and mid cingulate; (iv) bilateral dorsolateral, ventrolateral, and anterior prefrontal cortex. The detail of the posterior activation revealed by the place versus width contrast is revealed in Fig. 3 by using a lower threshold ( $P < 0.01$  uncorrected). Here we can see the continuous nature of the activation running between the precuneus and the parahippocampal cortex via the parieto-occipital sulcus and retrosplenial cortex and extending into the left hippocampus (and the right hippocampus below threshold:  $P < 0.003$  uncorrected).

The contrast of the equally context-dependent person condition versus width reveals a similar network of activations to the place versus width contrast, but without significant activation of the parahippocampal and ventrolateral prefrontal cortices, anterior cingulate, and left hippocampus. There is also significantly less activation of retrosplenial cortex (see Table 2). The same pattern of results is repeated in the comparison of place with object as in the comparison with width, although the left hippocampal activation falls below threshold (see Table 3). The contrast of person with object is similar to the comparison with width except that the left ventrolateral prefrontal cortex and anterior cingulate are now above threshold, while the right dorsolateral prefrontal cortex falls below threshold (see Table 4).

The comparison of object with width is shown on Table 5, comprising much weaker activation in the

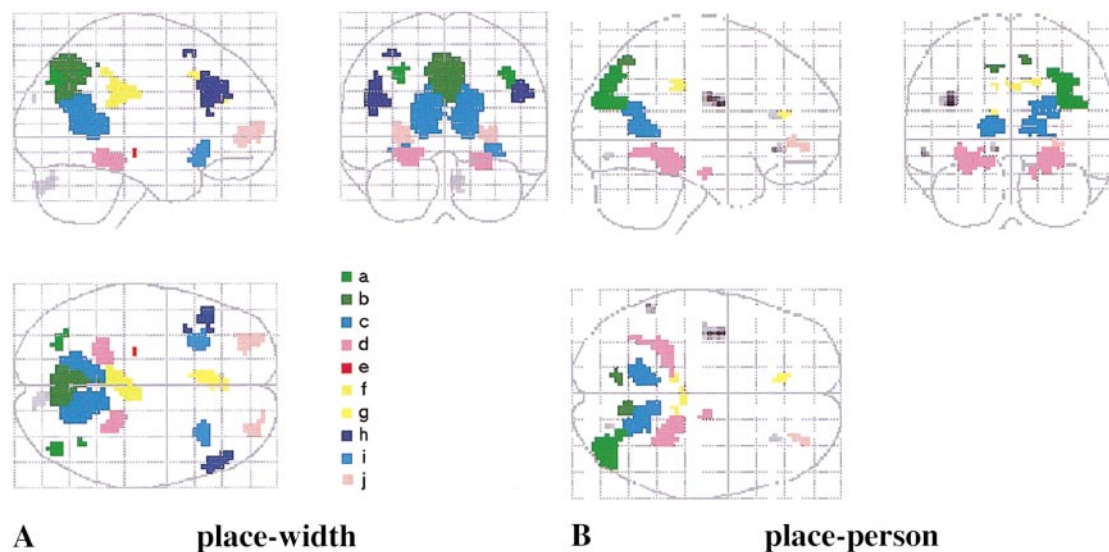


**FIG. 1.** (A) The event of receiving an object. (B) A paired forced choice question relating to place.

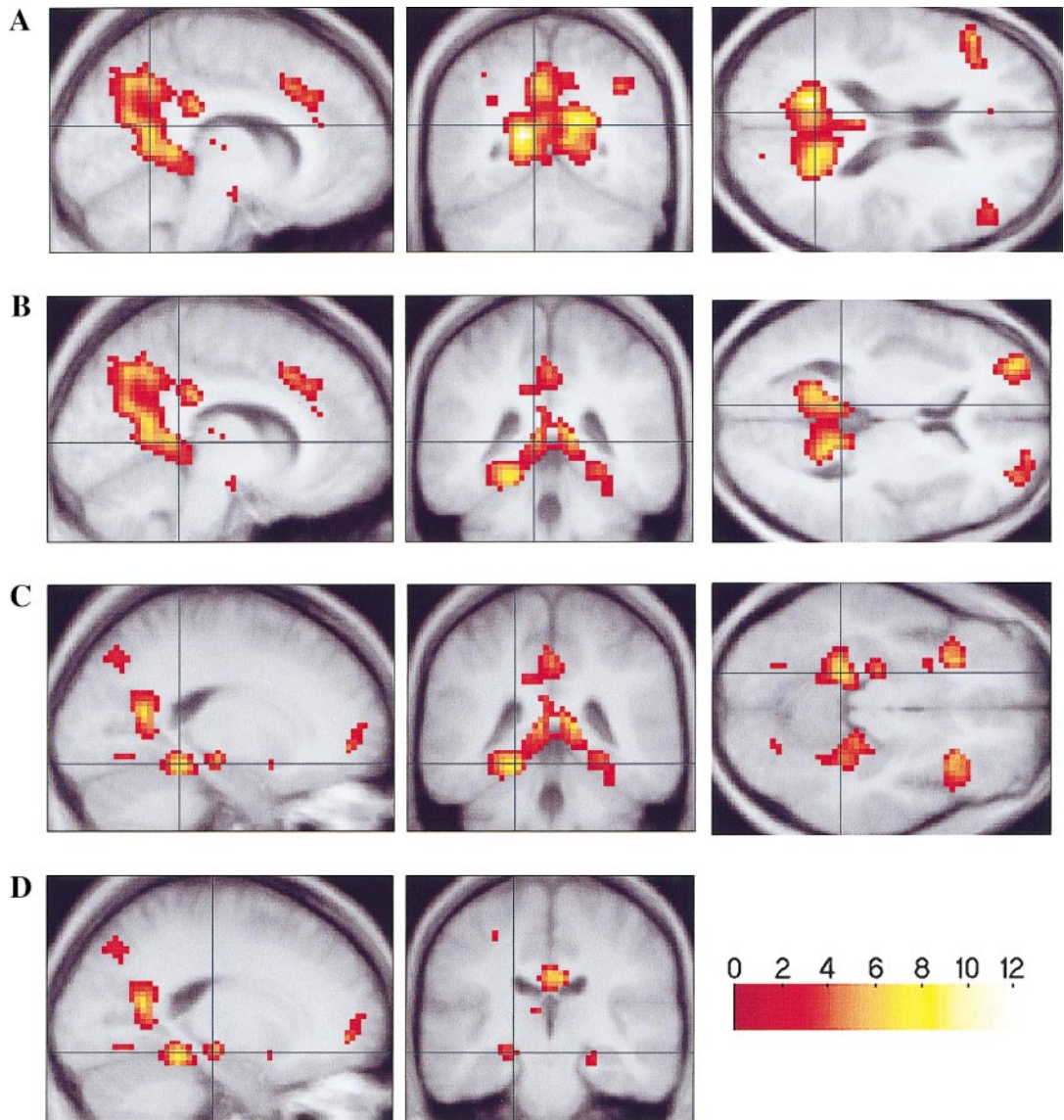
precuneus and parieto-occipital sulcus and additional activation in the right fusiform gyrus. The (relatively posterior) fusiform area activated in this contrast was not significantly activated in the contrasts of object with person or place, although a nearby region of the right inferior temporal gyrus (BA 37) was active in both these contrasts (object–person: 48 –69 –12,  $Z = 5.11$ ; object–place: 51 –66 –18,  $Z = 4.6$ ), as was an anterior right fusiform area (BA 20, object–person: 33 –24 –27,  $Z = 3.42$ ; object–place: 42 –9 –33,  $Z = 3.77$ ). Activations seen in these latter contrasts, but not in the contrast with width, presumably reflect the extra attention paid to the objects themselves in the object and width conditions compared to the place and person conditions. As we did not have specific predictions for these contrasts the threshold of  $P < 0.05$  corrected for multiple comparisons was applied. Significant activa-

tion was seen in the right inferior temporal gyrus in object versus person (see above) and an area in the right intra parietal sulcus in object versus place (BA 40, 54 –27 48,  $Z = 5.18$ ; also activated, subthreshold, in object–person: 42 –39 39,  $Z = 3.61$ ). Consistent, subthreshold, activation in the contrast of object with both place and person was also seen in the right inferior frontal gyrus (BA9/44, object–person: 57 9 9,  $Z = 4.44$ ; object–place: 51 9 18,  $Z = 4.39$ ).

The areas explicitly involved in the memory for spatial context as opposed to the memory for person are shown by the direct contrast of place versus person, see Figure 2B and Table 6. The main areas revealed in this contrast are bilateral posterior parahippocampal and retrosplenial cortices, extending on the right to a lateral posterior parietal area via the parieto-occipital sulcus. Of the large precuneal activation in the con-



**FIG. 2.** Significant activations in the place-width (A) and place-person (B) contrasts are shown in color on the glass brain ( $P < 0.001$  uncorrected for multiple comparisons for activations corresponding to the predicted areas of interest, and  $P < 0.05$  corrected for activations in other areas, see Materials and Methods). Other activations are shown in grey. The sagittal (from the right), coronal (from behind), and horizontal (from above) views of a glass brain are shown. Color scheme: (a) posterior parietal; (b) precuneus; (c) parieto-occipital sulcus and retrosplenial cortex; (d) parahippocampal gyrus; (e) hippocampus; (f) midposterior cingulate; (g) anterior cingulate; (h) dorsolateral prefrontal cortex; (i) ventrolateral prefrontal cortex; (j) anterior prefrontal cortex. The activation in the left insula shown in grey in (b) falls just below significance for areas outside those predicted to be of interest (Brodmann area 4; coordinate –39 –6 24;  $Z = 4.17$ ;  $P < 0.07$  corrected).



**FIG. 3.** Detail of the posterior activation in the place-width contrast are shown on sagittal, coronal, and horizontal sections through the average structural MR scan of the subjects. The threshold of  $P < 0.01$  uncorrected reveals a continuous strip of activation between the precuneus and parieto-occipital sulcus (A) and hippocampus (D) via the retrosplenial cortex (B) and to posterior parahippocampal gyrus (C). Note the much weaker activation of the right than left hippocampus (C and D). Color scheme in bottom right shows  $Z$  score equivalents.

trast of place with object or width, only a posteriodorsal region (BA7) is significantly activated in this contrast. We note the presence of a more anterior and dorsomedial right parahippocampal activation and a (sub-threshold) left insular activation in this contrast (see Fig. 2B). These activations are difficult to interpret as they were not present in the basic place versus width, and thus reflect a deactivation in the person condition relative to width.

In the opposite contrast of person versus place, one area of activation fell into our areas of interest: mid cingulate (BA 31, 3–12 48,  $Z = 3.29$ ), while activation in the left superior temporal gyrus/temporal pole (BA 38, –57 15 –6,  $Z = 3.75$  and –33 12 –39,  $Z = 3.35$ )

were consistent with previous studies of autobiographical memory (Maguire and Mummery, 1999; Maguire *et al.*, 2000). Other activations, in the posterior left superior temporal gyrus (BA39 –60 –48 12,  $Z = 3.22$ ) and right intraparietal sulcus (BA7/40, 42 –45 63,  $Z = 3.39$ ), neither survived correction for multiple comparisons nor were predicted by previous studies.

To better characterize the involvement of several regions, their activation in all memory conditions are shown in Fig. 4 (relative to baseline). We can see that the bilateral parahippocampal and posterior parietal cortices and the precuneal area in BA7 are primarily activated by the place condition. The right hippocampal area revealed at the lower threshold in Fig. 3 is also

TABLE 1

Regional Activations in the Place–Width Contrast			
Location	Brodman area	Coordinates	Z score
L POS/retrosplenial	17/18/23/29/30/31	–15 –60 18	5.49
R POS/retrosplenial	17/18/23/29/30/31	18 –69 24	5.06
Precuneus	31/23/7	3 –69 30	5.24
R vlpfc	47	30 24 –6	4.49
L vlpfc	47	–27 24 –9	4.03
L parahippocampus	35	–21 –42 –15	4.42
R parahippocampus	35	24 –33 –18	3.65
L anterior prefrontal cortex	10	–27 51 –3	4.41
R anterior prefrontal cortex	10	30 57 3	4.03
Mid cingulate cortex	23	–6 –30 30	4.41
R dlpc	9/44	54 30 30	4.31
L dlpc	9/44	–48 27 21	4.03
L frontal cortex	6	–36 15 57	3.63
R posterior parietal cortex	39/40	42 –75 39 39 –57 42	4.14 3.43
L posterior parietal cortex	39/40	–27 –72 39	3.44
Anterior cingulate	24	–6 21 39	3.96
L hippocampus		–21 –21 –9	3.57
L fusiform gyrus	19	–24 –69 –9	3.56

Note. Areas of significant activation are shown ( $P < 0.001$  uncorrected for multiple comparisons for predicted areas of interest,  $P < 0.05$  corrected in other areas and a minimum extent threshold of at least 3 voxels, see Methods). The first coordinate ( $xyz$ ) against an area indicates the location of the peak activation in the named area, further coordinates represent secondary peaks of activation. Abbreviations: right (R); left (L); parieto-occipital sulcus (POS); ventrolateral prefrontal cortex (vlpc); dorsolateral prefrontal cortex (dlpc); superior (sup).

primarily activated by the place condition. Thus the activation of all these areas probably reflects specifically spatial processing within context-dependent memory. By contrast, the bulk of the precuneus (BA 31/23), left dorso- and ventrolateral prefrontal cortices and the right anterior frontal region show no difference in the pattern of activation between the place and person conditions. These areas are clearly involved in general aspects of context-dependent episodic retrieval not specific to which aspect of context (who or where) is being retrieved. The remaining areas activated in the contrast of place with width show an intermediate pattern: graded response to the place, person, object, and width conditions. Thus, while indeed showing a degree of specificity for spatial context, the pattern of activation in these regions (including the left hippocampus) indicate involvement in context-dependent memory retrieval, but do not allow unambiguous interpretation of their role.

## DISCUSSION

By combining efMRI and a novel VR paradigm, we have been able to investigate the neural basis of re-

TABLE 2

Regional Activations in the Person–Width Contrast			
Location	Brodman areas	Coordinates	Z score
R POS/retrosplenial	17/18/23/29/30/31	15 –63 27	5.33
L POS/retrosplenial	17/18/23/29/30/31	–15 –60 18	4.75
Precuneus	7/23/31	0 –66 27	5.1
R dlpc	9/44	48 36 30	4.34
L dlpc	9/44	–48 30 33 –45 24 24	3.6 3.25
R anterior prefrontal cortex	10	30 57 3	4.05
L anterior prefrontal cortex	10	–30 57 0	3.79
R posterior parietal cortex	39/40	39 –54 45	3.87
L posterior parietal cortex	39/40	–36 –66 45	3.44
Mid cingulate cortex	23	6 –21 24 –3 –42 15 –3 –21 12	3.75 3.66 3.23

trieval of the spatial context of lifelike events for the first time. Consistent with previous functional neuroimaging studies using conventional laboratory stimuli, we found extensive prefrontal cortical and medial parietal activation. Interestingly we also found medial temporal activation, consistent with neuropsychological studies and some functional neuroimaging studies of autobiographical memory. We consider these anterior and posterior activations in more detail below.

TABLE 3

Regional Activations in the Place–Object Contrast			
Location	Brodman area	Coordinates	Z score
Precuneus	7/23/31	9 –66 48	5.2
R POS	17/18/23/29/30/31	12 –48 6	3.72
L POS	17/18/23/29/30/31	–9 –45 6	3.59
L anterior prefrontal cortex	10	–27 54 –6 –24 51 18	4.94 3.86
R anterior prefrontal cortex	10	24 60 6	4.49
R posterior parietal cortex	39/40	42 –72 42 45 –63 45	4.55 3.45
L posterior parietal cortex	39/40	–36 –69 24 –51 –72 24	3.6 3.48
L vlpfc	47	–42 24 –15	4.44
R vlpfc	47	33 24 –12	3.5
Anterior cingulate cortex	24	6 39 30	4.25
Mid cingulate cortex	23	–3 –33 42	4.17
L dlpc	9/44	–42 21 39	4.12
	8	–27 27 54	3.45
R dlpc	9	45 42 30	3.68
L parahippocampus	35	–24 –42 –15	4.02
R parahippocampus	35	27 –39 –12	3.92

TABLE 4

Regional Activations in the Person–Object Contrast			
Location	Brodman area	Coordinates	Z score
Precuneus	7/23/31	–6 –72 33	5.51
L dlpc	8	–39 12 48	4.94
	9/44	–42 27 36	3.93
L anterior prefrontal cortex	10	–33 57 12	4.24
		–27 51 24	4.22
		–18 36 39	3.95
R anterior prefrontal cortex	10	24 60 0	4.04
L vlpfc	47	–48 24 –9	4.19
		–30 21 –15	3.42
L posterior parietal cortex	39/40	–36 –78 42	3.93
R posterior parietal cortex	39/40	48 –57 45	3.7
Anterior cingulate cortex	24	–3 39 39	3.76
Mid cingulate cortex	23	–3 –33 24	3.7

### Posterior Activations

We have demonstrated the involvement of a temporoparietal network involved in the recall of the spatial context of an event. This network extends from the precuneus bilaterally down the parieto-occipital sulcus into posterior parahippocampal cortex via retrosplenial cortex, and includes bilateral posterior parietal, mid to posterior cingulate, and left hippocampus. Of these areas bilateral parieto-occipital sulcus, parahippocampal and right posterior parietal cortex, and BA7 (also right hippocampus, subthreshold) are specifically activated by the retrieval of where the event happened compared to whom it involved. By contrast, the bulk of the precuneus is equally activated in both conditions. Overall, there is a slight left lateralization despite the use of visual rather than verbal stimuli and the spatial nature of the place task.

What do these results tell us regarding the role of the hippocampus in episodic memory? The interpretation of our results is aided by having used the same tasks in neuropsychological studies. Briefly, a patient with hippocampal pathology due to perinatal anoxia (Vargha-

TABLE 5

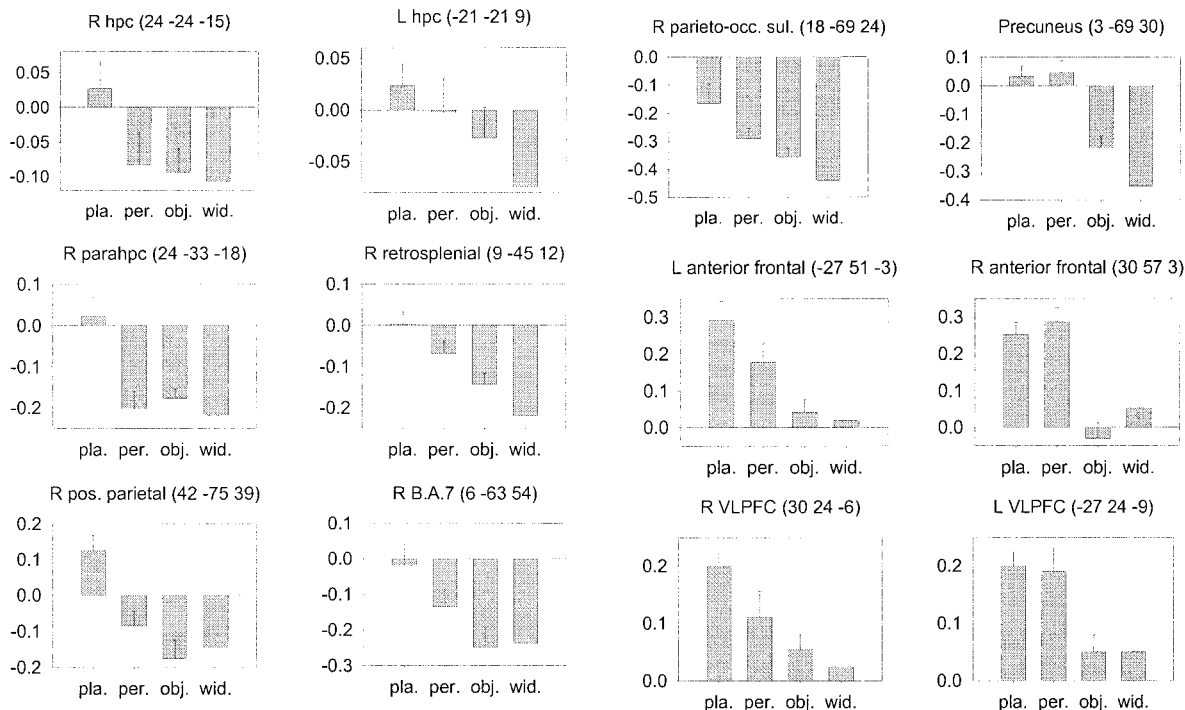
Regional Activations in the Object–Width Contrast			
Location	Brodman area	Coordinates	Z score
R POS/retrosplenial	17/18/23/29/30/31	15 –54 12	3.74
		18 –63 24	3.18
L POS/retrosplenial	17/18/23/29/30/31	–15 –66 21	3.71
		–15 –57 15	3.46
R fusiform gyrus	37	30 –45 –21	3.53
	19	33 –84 –12	3.23
	19	30 –72 –12	3.23

TABLE 6

Regional Activations in the Place–Person Contrast			
Location	Brodman area	Coordinates	Z score
R sup. occipital gyrus	19	33 –81 27	4.35
L POS/retrosplenial	18/17/23/29/30/31	–12 –54 9	4.31
R POS/retrosplenial		32 –54 6	4.11
Precuneus	7	6 –63 54	4.24
		–12 –72 48	3.42
R parahippocampus	35	21 –36 –9	4.24
		30 –45 –12	3.94
	27/28	15 –15 –21	3.91
L parahippocampus	27/28	–30 –39 –18	3.74
		–15 –36 –15	3.56
R anterior prefrontal	10/32	30 45 –3	4.09
		30 30 15	3.26
L anterior prefrontal	10/32	–9 30 –6	3.74
		–12 36 18	3.6
R posterior parietal cortex	39/40	33 –75 39	3.94
Mid cingulate cortex	23	18 –33 39	3.90
		3 –27 36	3.62
		–9 –33 36	3.5

Khadem *et al.*, 1997) performed at chance on the place and person questions, but was unimpaired on the object question (Spiers *et al.*, 2001). A group of left unilateral temporal lobectomy patients (TLPs) were impaired on the place and person questions, while right TLPs performed at a level intermediate to the left group and controls. By contrast, the right TLPs were impaired on a spatial navigation task and the left TLPs were not (Spiers *et al.*, in preparation). These results imply that the left hippocampal activation we observed in the place condition reflects processing of context necessary for the task, as does the subthreshold activation in the person condition, while the much weaker activation in the object condition does not (see Fig. 4).

The occurrence of more significant left than right hippocampal activation in the contrast of place and width, together with the previous finding of greater right hippocampal activation during spatial navigation in the VR town (Maguire *et al.*, 1998), corresponds well to the above patient studies. Overall these results imply a lateralization of hippocampal function with the left more involved in context-dependent episodic memory, and the right more involved in spatial navigation. This is consistent with the interpretation of previous findings of hippocampal activations during navigation, in which activation on the right was associated with geometric processes specific to accurate navigation while that on the left was associated with more general episodic memory (Maguire *et al.*, 1998a; Grön *et al.*, 2000). These results are also consistent with the association of the right medial temporal lobe with memory for the locations of objects (Smith and Milner, 1981; Nunn *et al.*, 1999; Abrahams *et al.*, 1999); some of these tasks may be mediated by the parahippocampus



**FIG. 4.** Parameter estimates across all conditions. Examples of areas primarily responding to the retrieval of spatial context (place, shown on the left), areas responding equally in both context-dependent retrieval tasks (place and person, shown on the right), and areas with intermediate responses (shown in the middle). Where the same pattern of response is shown in both left and right hemispheres, the area on the right is shown. Conditions: place (pla), person (per), object (obj), width (wid). Error bars show the standard error of the mean of the difference between the parameter estimate for that condition and the parameter estimate for the width condition (i.e., the quantity subjected to a *T* test for significant activation in the contrast with width in Figs. 2 and 3 and Tables 1, 2, and 6). See Materials and Methods. All plots show the parameter estimate for the voxel of peak activation in the contrast of place and width except for the plot for the subthreshold right hippocampal activation shown in Fig. 3 and the right BA7 area activated in place-person.

(Johnsrude *et al.*, 1999), although a patient with focal hippocampal damage was found to be impaired on a test of allocentric spatial memory (Holdstock *et al.*, 2000). Our results also provide an interesting parallel to the association of the left medial temporal lobe with memory for the content of verbal stories (Frisk and Milner, 1990). Since our task was nonverbal, and not explicitly verbally mediated, this suggests a common mechanism in the left hippocampus for narrative and events, possibly storing narrative by treating it as personal experience. Interestingly, the right hippocampus appears to be specifically involved in the place condition, albeit subthreshold. This may relate to the involvement of the right hemisphere in the long-term storage of the spatial components of prose passages (Martin *et al.*, 1990). It may also indicate a possible evolutionary route for left hippocampal function from a spatial to an episodic system via retrieval of spatial context (and reconstruction of the scene of the event). However, the left hippocampal involvement in the person condition implies that its role in episodic memory is now more than simple retrieval of spatial context as an aid to retrieval of other aspects of the event. It is difficult to tell if the slightly greater left hippocampal activation for place rather than person reflects a greater realism of the spatial context compared to the

people or reflects a vestigial preferential involvement in spatial context.

The activation of the entire length of the parieto-occipital sulcus and right posterior parietal cortex (as seen in our place-person contrast) was also observed during the recall of routes around London by taxi drivers (Maguire *et al.*, 1997). This may indicate a similar process of recalling allocentric spatial information from long term memory: the increased left posterior parietal activation and reduced activation of the precuneus in the taxi driver study may relate to the use of verbal recall in that study. The retrosplenial involvement in the context-dependent memory conditions here, and in previous imaging studies using autobiographical stimuli (Fink *et al.*, 1996; Maguire and Mummery, 1999; Maguire *et al.*, 2000), implies that this region plays an important role in episodic recall. This is corroborated by the observation of retrosplenial amnesia (Valenstein *et al.*, 1987; Masuo *et al.*, 1999). The parahippocampal areas activated here show good correspondence to the location of the area activated by viewing spatial scenes (Epstein and Kanwisher, 1998) (peak activations at:  $-20, -39, -5$  and  $28, -39, -6$ ). In their study differential activation was observed as a function of the different types of visual stimuli presented, and imaging was restricted to a posterior and ventral por-

tion of the brain. Use of the same visual stimuli in all conditions and imaging of the entire brain allows us to demonstrate the involvement of this region in memory for spatial context and show how the response there relates to the responses in other parts of the memory network.

Several previous functional neuroimaging studies have failed to associate medial temporal regions with the retrieval of the spatial context of an event (Nyberg *et al.*, 1996; Rugg *et al.*, 1999; Henson *et al.*, 1999; Kohler *et al.*, 1998). In these studies, the event to be remembered is the appearance of a word or picture on a screen, and its location on the screen provides its spatial context (often simply to the left or to the right). One possible explanation of the difference between these results and ours may be that locations on a screen in front of a static observer are likely to be encoded egocentrically (e.g., relative to the observer's head), while locations in the VR town need to be located allocentrically due to the movement of the observer. Single unit studies in rats and primates implicate the parietal cortex in egocentric representations of location (Hyvarinen and Poranen, 1974; Mountcastle *et al.*, 1975; Andersen *et al.*, 1985) and the hippocampus and neighboring structures in allocentric representations of location (O'Keefe and Nadel, 1978; Rolls *et al.*, 1997).

To interpret the pattern of posterior activations we return to the model of retrieval from episodic memory outlined in the Introduction. Put simply, this states that long-term memory makes use of the allocentric representations found in medial temporal regions, whereas short-term memory, including the working memory required for imagery and action, makes use of egocentric representations found in the parietal lobe (Burgess *et al.*, 1999; Milner *et al.*, 1999). Under this model information regarding the event associated with getting one of the objects is retrieved from the hippocampus and used to generate an allocentric representation of the locations of the elements of the scene of the event in the parahippocampal gyrus. This representation is successively translated from allocentric to body-centered to head-centered representations with the aid of right posterior parietal cortex and BA7 into a viewpoint-dependent representation for visual imagery. These roles for BA7 have received support from a recent single-unit study (Snyder *et al.*, 1998). We assume that the precuneus supports inspection of the internal image, while the continuous strip of activation between the parahippocampus and precuneus reflects the buffering of successively translated representations of the scene of the event. The person condition also relies on imagery of an aspect of the context of an event, and its retrieval from long-term memory, explaining the activation of the precuneus and (sub-threshold) left hippocampus in this condition. However, it does not require that the spatial scene of the

event, including the relative locations of its components, be recalled, explaining the lack of the right parietal and parahippocampal to precuneus activation seen in the place condition. This mapping of function to structure is also consistent with the anatomical connections of both retrosplenial cortex (Morris *et al.*, 1999) and posterior parietal areas (BA7 (Burgess *et al.*, 1999; Andersen, 1997)) to the parahippocampus. For further details see (Burgess *et al.*, 1999) and (Becker and Burgess, 2000) for a computational model.

The activation of the right fusiform gyrus in the contrast of object versus width is consistent with activation of this area in memory for object identity in several previous studies (Kohler *et al.*, 1998; Moscovitch *et al.*, 1995; Postle *et al.*, 2000). The right inferior temporal, intraparietal and inferior frontal areas activated in the comparisons of object versus place and person (but not in comparison to width) may reflect extra attention to the features of the objects themselves. However, the object condition involves novel foil objects while all other conditions involve solely the familiar objects. Thus, while the right fusiform activations may reflect object-memory and the right inferior temporal and intraparietal activations processing of object features (see, e.g., Faillenot *et al.*, 1999), effects of novelty may also contribute to these activations, and most likely contribute to the activation of the right inferior frontal gyrus (see, e.g., Kirchoff *et al.*, 2000; Opitz *et al.*, 1999). We note that most of the activations present in comparing place or person with object were also present in the comparison with width, so that object familiarity probably did not make a large contribution to these activations. Interestingly, there was no evidence of greater activation in the fusiform face area (coordinates: 40 -55 -10) (Kanwisher *et al.*, 1997) in the person condition than in any of the other conditions. This lack of activation indicates that the faces of the virtual people were not strongly represented in memory, perhaps due to their low resolution, or were superseded by the presence of other obvious features by which the people could be distinguished (gender, clothing etc.; see Fig. 1).

### *Anterior Activations*

The retrieval of the spatial context of an event activates seven well-circumscribed prefrontal areas: anterior cingulate and bilateral dorsolateral, ventrolateral and anterior prefrontal cortex. The areas have a close correspondence to the areas classically activated in previous studies of episodic retrieval of laboratory stimuli (Lepage *et al.*, 2000), although they are not usually all activated in the same study. The consistency of the locations across many studies indicates that the prefrontal activations found here are both reliable and not specific to the stimuli used. These areas were all significantly activated in the contrasts of

place with object and with width. All but the ventrolateral areas and anterior cingulate were activated in the contrast of person and width, while all but the right dorso- and ventrolateral areas were activated in the contrast of person and object. While some of these areas, e.g., right ventro- and dorsolateral prefrontal, showed a greater response in the place condition than the person condition, none showed the strong spatial selectivity of response seen in some of the posterior areas (see Fig. 2B).

Comparison with the patterns of prefrontal activation associated with memory for object location versus object identity in previous studies are hard to interpret due to variability across studies: producing activation on the left (Nyberg *et al.*, 1996; Rugg *et al.*, 1999) right (Henson *et al.*, 1999), or not at all (Johnsrude *et al.*, 1999). The fairly uniform distribution of prefrontal activations seen in the place and person conditions (i.e., successful retrieval of visuospatial stimuli using interleaved conditions) is inconsistent with some models of prefrontal recruitment. For example dorsal recruitment by spatial stimuli (Goldman-Rakic, 1995), right recruitment by retrieval (Tulving *et al.*, 1994) or success (Rugg *et al.*, 1996; Buckner *et al.*, 1998a), or the need for an ongoing retrieval mode (Lepage *et al.*, 2000). It is consistent with the idea that anterior regions are recruited by post retrieval processing (Buckner *et al.*, 1998b; Allan *et al.*, 2000) insofar as source memory requires more of this than object recognition. Performance data indicate that the place and person conditions were more difficult than the object condition, so that effort cannot be ruled out as a factor. However, previous studies argue against effort, as indexed by reaction time, being a factor in the anterior activation (Henson *et al.*, 1999b; Konishi *et al.*, 2000).

The imaging studies of autobiographical memory using verbal stimuli that did activate medial temporal areas (Maguire and Mummery, 1999; Maguire *et al.*, 2000; Fink *et al.*, 1996) did not activate the range of prefrontal areas found here. Although these studies did not look specifically at retrieval of the location of events, we would expect retrieval of autobiographical stimuli to include retrieval of arbitrarily rich contexts, making context-dependent retrieval per se unlikely to be the cause of the greater prefrontal activation in our study. Three other differences between these studies and the present study are worth consideration. One difference concerns the earlier studies' use of verbal descriptions of past events, which would automatically engage verbal systems, and may not evoke as visually complete an image of the event as the representation of the context of the event used here. However, since extensive prefrontal activations are routinely found with conventional laboratory stimuli, we would not expect this to explain the greater frontal activation in the present study. A second difference concerns the relatively short time scale over which events were ex-

perienced in our study, i.e., the similarity in their temporal context. This difference may relate to some of the prefrontal activations in our study. The anterior cingulate has been implicated in retrieval of temporal context (Nyberg *et al.*, 1996), while right ventrolateral prefrontal activation has been associated with the retrieval of recent relative to remote events (Maguire *et al.*, 2001). More generally, frontal damage leads to impaired memory for the temporal order of recent events (Milner *et al.*, 1985). A third difference is the similar nature of the events used in our study compared to the rich diversity of the events used in autobiographical studies (e.g., being at a wedding, going to the dentist, etc.). This doubtless causes greater interference during retrieval, which may explain the recruitment of the dorsolateral and anterior prefrontal areas not seen in autobiographical studies.

Such an interpretation of the prefrontal role in episodic retrieval is consistent with neuropsychological studies. Lesions to medial or ventral prefrontal cortex or to frontotemporal connections can impair episodic retrieval (see, e.g., Levine *et al.*, 1998; Warrington and Weiskrantz, 1982), including source memory for which of two lists a given word came from (e.g., Janowsky *et al.*, 1989). However, frontal damage and, particularly, anterior and dorsolateral damage does not cause the dense amnesia seen after bilateral medial temporal damage (see, e.g., Burgess and Shallice, 1996, p. 392; Moscovitch, 1995; Moscovitch and Melo, 1997). Explicit comparisons of the effects of lesions to the frontal and temporal lobes implicate the medial temporal lobes in the storage of episodic memory and the frontal lobes in the use of organisational strategies in encoding and retrieval (Incisa-della and Milner, 1993; Smith *et al.*, 1995; Frisk and Milner, 1990; Gershberg and Shimamura, 1995; Owen *et al.*, 1996; Kopelman and Stanhope, 1998), including those required to cope with the interference between items and lists (Incisa-della and Milner, 1993; Smith *et al.*, 1995).

## CONCLUSIONS

There has been a puzzling tendency for episodic retrieval of conventional laboratory stimuli, such as lists of words, to produce anterior or dorsolateral prefrontal activation rather than medial temporal activation. This is at odds with the neuropsychological evidence relating the medial temporal lobes to amnesia and prefrontal regions with the application of strategy, including the strategic organisation of retrieval. It also contrasts with studies of autobiographical memory that have activated medial temporal regions but not anterior or dorsolateral prefrontal ones. In our study, the retrieval of the spatial context of lifelike but similar events activates both medial temporal and prefrontal systems. We conclude that the rich nature of the context (specifically their spatial context) of the simu-

lated events in our study, as with autobiographical studies, contributes to medial temporal involvement. Conversely, the similarity between the events used in our study and in studies using conventional laboratory stimuli, compared to the diversity and extended time scale of autobiographical stimuli, contributes to the involvement of prefrontal regions.

While conventional laboratory stimuli allow for great experimental control, memory for events in real life usually concern complex interactions with rather perceptually rich stimuli. In this study we have demonstrated activation of a well circumscribed but extensive temporal, parietal, and prefrontal network in a test of memory for the location of controlled but lifelike events. A continuous temporoparietal strip of activation from parahippocampal cortex to precuneus was observed, in conjunction with posterior parietal, hippocampal, and prefrontal activations. The posterior activations are consistent with a model of imagery and episodic recall based on long-term storage of allocentric information in medial temporal areas that is translated into an imageable viewpoint dependent representation in the precuneus. The prefrontal areas correspond to the entire set of areas reliably implicated in previous studies of episodic recall of conventional laboratory stimuli. The activation of these areas, particularly the dorsolateral and anterior ones, may correspond to areas engaged in strategic retrieval processes relating to the interference caused by the similar nature of the events.

### ACKNOWLEDGMENTS

We acknowledge useful discussions with Paul Burgess, Rik Henson, and Mick Rugg and technical help from Rik Henson, Oliver Josephs, and Karl Friston. This work was supported by an MRC project grant to N.B., J.O'K., and F. Vargha-Khadem, an MRC programme grant to J.O'K., and by the Wellcome Trust, who also support E.A.M. N.B. is a Royal Society research fellow.

### REFERENCES

- Abrahams, S., Morris, R. G., Polkey, C. E., Jarosz, J. M., Cox, T. C., Graves, M., and Pickering, A. 1999. Hippocampal involvement in spatial and working memory: A structural MRI analysis of patients with unilateral mesial temporal lobe sclerosis. *Brain Cogn.* **41**: 39–65.
- Aggleton, J. P., and Brown, M. W. 1999. Episodic memory, amnesia, and the hippocampal-anterior thalamic axis. *Behav. Brain Sci.* **22**: 425–490.
- Aguirre, G. K., Detre, J. A., Alsop, D. C., and D'Esposito, M. 1996. The parahippocampus subserves topographical learning in man. *Cereb. Cortex* **6**: 823–829.
- Allan, K., Dolan, R. J., Fletcher, P. C., and Rugg, M. D. 2000. The role of the right anterior prefrontal cortex in episodic retrieval. *NeuroImage* **11**: 217–227.
- Alsaadi, T., Binder, J. R., Lazar, R. M., Doorani, T., and Mohr, J. P. 2000. Pure topographic disorientation: A distinctive syndrome with varied localization. *Neurology* **54**: 1864–1866.
- Andersen, R. A. 1997. Multimodal integration for the representation of space in the posterior parietal cortex. *Philos. Trans. R. Soc. London B Biol. Sci.* **352**: 1421–1428.
- Andersen, R. A., Essick, G. K., and Siegel, R. M. 1985. Encoding of spatial location by posterior parietal neurons. *Science* **230**: 456–458.
- Andreasen, N. C., O'Leary, D. S., Cizadlo, T., Arndt, S., Rezai, K., Watkins, G. L., Ponto, L. L., and Hichwa, R. D. 1995. II. PET studies of memory: Novel versus practiced free recall of word lists. *NeuroImage* **2**: 296–305.
- Baddeley, A. D., and Leiber, K. 1980. Spatial working memory. In *Attention and Performance VIII*. Lawrence Erlbaum Associates, Hillsdale, NJ.
- Baxendale, S. A., Thompson, P. J., and Van Paesschen, W. 1998. A test of spatial memory and its clinical utility in the presurgical investigation of temporal lobe epilepsy patients. *Neuropsychologia* **36**: 591–602.
- Baxendale, S. A., Van Paesschen, W., Thompson, P. J., Duncan, J. S., Shorvon, S. D., and Connelly, A. 1997. The relation between quantitative MRI measures of hippocampal structure and the intracarotid amobarbital test. *Epilepsia* **38**: 998–1007.
- Becker, S., and Burgess, N. A model of spatial recall, mental imagery and neglect. *Advances in neural information processing systems* **13**. In Press
- Bisiach, E., and Luzzatti, C. 1978. Unilateral neglect of representational space. *Cortex* **14**: 129–133.
- Bohbot, V. D., Kalina, M., Stepankova, K., Spackova, N., Petrides, M., and Nadel, L. 1998. Spatial memory deficits in patients with lesions to the right hippocampus and to the right parahippocampal cortex. *Neuropsychologia* **36**: 1217–1238.
- Buckner, R. L., Koutstaal, W., Schacter, D. L., Dale, A. M., Rotte, M., and Rosen, B. R. 1998b. Functional-anatomic study of episodic retrieval. II. Selective averaging of event-related fMRI trials to test the retrieval success hypothesis. *NeuroImage* **7**: 163–175.
- Buckner, R. L., Koutstaal, W., Schacter, D. L., Wagner, A. D., and Rosen, B. R. 1998a. Functional-anatomic study of episodic retrieval using fMRI. I. Retrieval effort versus retrieval success. *NeuroImage* **7**: 151–162.
- Buckner, R. L., Raichle, M. E., Miezin, F. M., and Petersen, S. E. 1996. Functional anatomic studies of memory retrieval for auditory words and visual pictures. *J. Neurosci.* **16**: 6219–6235.
- Burgess, N., Jeffery, K. J., and O'Keefe, J. 1999. Intergrating hippocampal and parietal functions: A spatial point of view. In *The Hippocampal and Parietal Foundations of Spatial Cognition* (N. Burgess, K. J. Jeffery, and J. O'Keefe, Eds.), pp. 3–29. Oxford Univ. Press.
- Burgess, P. W., and Shallice, T. 1996. Confabulation and the control of recollection. *Memory* **4**: 359–411.
- Cooper, B. G., and Mizumori, S. J. 1999. Retrosplenial cortex inactivation selectively impairs navigation in darkness. *Neuroreport* **10**: 625–630.
- Desgranges, B., Baron, J. C., and Eustache, F. 1998. The functional neuroanatomy of episodic memory: The role of the frontal lobes, the hippocampal formation, and other areas. *NeuroImage* **8**: 198–213.
- Eldridge, L. L., Knowlton, B. J., Furmanski, C. S., Bookheimer, S. Y., and Engel, S. A. 2000. Remembering episodes: A selective role for the hippocampus during retrieval. *Nat. Neurosci.* **3**: 1149–1152.
- Epstein, R., and Kanwisher, N. 1998. A cortical representation of the local visual environment. *Nature* **392**: 598–601.
- Faillenot, I., Decety, J., and Jeannerod, M. 1999. Human brain activity related to the perception of spatial features of objects. *NeuroImage* **10**: 114–124.

- Fink, G. R., Markowitsch, H. J., Reinkemeier, M., Bruckbauer, T., Kessler, J., and Heiss, W. D. 1996. Cerebral representation of one's own past: Neural networks involved in autobiographical memory. *J. Neurosci.* **16**: 4275–4282.
- Fletcher, P. C., Frith, C. D., Baker, S. C., Shallice, T., Frackowiak, R. S. J., and Dolan, R. J. 1995. The mind's eye—Precuneus activation in memory-related imagery. *NeuroImage* **2**: 195–200.
- Fletcher, P. C., Frith, C. D., and Rugg, M. D. 1997. The functional neuroanatomy of episodic memory. *Trends Neurosci.* **20**: 213–218.
- Frisk, V., and Milner, B. 1990. The role of the left hippocampal region in the acquisition and retention of story content. *Neuropsychologia* **28**: 349–359.
- Friston, K. J., Fletcher, P., Josephs, O., Holmes, A., Rugg, M. D., and Turner, R. 1998. Event-related fMRI: Characterizing differential responses. *NeuroImage* **7**: 30–40.
- Gardiner, J. M., and Java, R. I. 1993. In *Theories of Memory* (A. Collins, S. Gathercole, and P. Morris, Eds.), pp. 168–188. Erlbaum, Hillsdale, NJ.
- Gershberg, F. B., and Shimamura, A. P. 1995. Impaired use of organizational strategies in free recall following frontal lobe damage. *Neuropsychologia* **33**: 1305–1333.
- Ghaem, O., Mellet, E., Crivello, F., Tzourio, N., Mazoyer, B., Berthoz, A., and Denis, M. 1997. Mental navigation along memorized routes activates the hippocampus, precuneus, and insula. *Neuroreport* **8**: 739–744.
- Goldman-Rakic, P. S. 1995. Architecture of the prefrontal cortex and the central executive. *Ann. N.Y. Acad. Sci.* **769**: 71–83.
- Goodale, M. A., and Milner, A. D. 1992. Separate visual pathways for perception and action. *Trends Neurosci.* **15**: 20–25.
- Grasby, P. M., Frith, C. D., Friston, K. J., Bench, C., Frackowiak, R. S., and Dolan, R. J. 1993. Functional mapping of brain areas implicated in auditory—Verbal memory function. *Brain* **116**: 1–20.
- Gron, G., Wunderlich, A. P., Spitzer, M., Tomczak, R., and Riepe, M. W. 2000. Brain activation during human navigation: Gender-different neural networks as substrate of performance. *Nat. Neurosci.* **3**: 404–408.
- Guariglia, C., Padovani, A., Pantano, P., and Pizzamiglio, L. 1993. Unilateral neglect restricted to visual imagery. *Nature* **364**: 235–237.
- Henson, R. N., Rugg, M. D., Shallice, T., Josephs, O., and Dolan, R. J. 1999b. Recollection and familiarity in recognition memory: An event-related functional magnetic resonance imaging study. *J. Neurosci.* **19**: 3962–3972.
- Henson, R. N., Shallice, T., and Dolan, R. J. 1999. Right prefrontal cortex and episodic memory retrieval: A functional MRI test of the monitoring hypothesis. *Brain* **122**: 1367–1381.
- Heun, R., Klose, U., Jessen, F., Erb, M., Papassotiropoulos, A., Lotze, M., and Grodd, W. 1999. Functional MRI of cerebral activation during encoding and retrieval of words. *Hum. Brain Mapp.* **8**: 157–169.
- Holdstock, J. S., Mayes, A. R., Cezayirli, E., Isaac, C. L., Aggleton, J. P., and Roberts, N. 2000. A comparison of egocentric and allocentric spatial memory in a patient with selective hippocampal damage. *Neuropsychologia* **38**: 410–425.
- Hyvarinen, J., and Poranen, A. 1974. Function of the parietal associative area 7 as revealed from cellular discharges in alert monkeys. *Brain* **97**: 673–692.
- Incisa della Rochetta, A., and Milner, B. 1993. Strategic search and retrieval inhibition: The role of the frontal lobes. *Neuropsychologia* **31**: 503–524.
- Janowsky, J. S., Shimamura, A. P., and Squire, L. R. 1989. Source memory impairment in patients with frontal lobe lesions. *Neuropsychologia* **27**: 1043–1056.
- Johnsrude, I. S., Owen, A. M., Crane, J., Milner, B., and Evans, A. C. 1999. A cognitive activation study of memory for spatial relationships. *Neuropsychologia* **37**: 829–841.
- Kanwisher, N., McDermott, J., and Chun, M. M. 1997. The fusiform face area: A module in human extrastriate cortex specialized for face perception. *J. Neurosci.* **17**: 4302–4311.
- Kirchhoff, B. A., Wagner, A. D., Maril, A., and Stern, C. E. 2000. Prefrontal-temporal circuitry for episodic encoding and subsequent memory. *J. Neurosci.* **20**: 6173–6180.
- Knowlton, B. J., and Squire, L. R. 1995. Remembering and knowing: Two different expressions of declarative memory. *J. Exp. Psychol. Learn. Mem. Cogn.* **21**: 699–710.
- Kohler, S., Moscovitch, M., Winocur, G., Houle, S., and McIntosh, A. R. 1998. Networks of domain-specific and general regions involved in episodic memory for spatial location and object identity. *Neuropsychologia* **36**: 129–142.
- Konishi, S., Wheeler, M. E., Donaldson, D. I., and Buckner, R. L. 2000. Neural correlates of episodic retrieval success. *NeuroImage* **12**: 276–286.
- Kopelman, M. D., and Stanhope, N. 1998. Recall and recognition memory in patients with focal frontal, temporal lobe and diencephalic lesions. *Neuropsychologia* **36**: 785–795.
- Kopelman, M. D., Wilson, B. A., and Baddeley, A. D. 1989. The autobiographical memory interview: A new assessment of autobiographical and personal semantic memory in amnesic patients. *J. Clin. Exp. Neuropsychol.* **11**: 724–744.
- Krause, B. J., Horwitz, B., Taylor, J. G., Schmidt, D., Mottaghy, F. M., Herzog, H., Halsband, U., and Muller, G. H. 1999. Network analysis in episodic encoding and retrieval of word-pair associates: A PET study. *Eur. J. Neurosci.* **11**: 3293–3301.
- Lepage, M., Ghaffar, O., Nyberg, L., and Tulving, E. 2000. Prefrontal cortex and episodic memory retrieval mode. *Proc. Natl. Acad. Sci. USA* **97**: 506–511.
- Levine, B., Black, S. E., Cabeza, R., Sinden, M., McIntosh, A. R., Toth, J. P., Tulving, E., and Stuss, D. T. 1998. Episodic memory and the self in a case of isolated retrograde amnesia. *Brain* **121**: 1951–1973.
- Maguire, E. A., Burgess, N., Donnett, J. G., Frackowiak, R. S., Frith, C. D., and O'Keefe, J. 1998. Knowing where and getting there: A human navigation network. *Science* **280**: 921–924.
- Maguire, E. A., Burke, T., Phillips, J., and Staunton, H. 1996. Topographical disorientation following unilateral temporal lobe lesions in humans. *Neuropsychologia* **34**: 993–1001.
- Maguire, E. A., Frackowiak, R. S. J., and Frith, C. D. 1997. Recalling routes around London: Activation of the right hippocampus in taxi drivers. *J. Neurosci.* **17**: 7103–7110.
- Maguire, E. A., Burgess, N., Donnett, J. G., O'Keefe, J., and Frith, C. D., 1998b. Knowing where things are parahippocampal involvement in encoding object locations in virtual large-scale space. *J. Cogn. Neurosci.* **10**: 61–76.
- Maguire, E. A., Henson, R. N., Mummery, C. J., and Frith, C. D. 2001. Activity in right prefrontal cortex, but not hippocampus, varies parametrically with the increasing remoteness of memories. *Neuroreport* **12**: 441–444.
- Maguire, E. A., and Mummery, C. J. 1999. Differential modulation of a common memory retrieval network revealed by positron emission tomography. *Hippocampus* **9**: 54–61.
- Maguire, E. A., Mummery, C. J., and Buchel, C. 2000. Patterns of hippocampal-cortical interaction dissociate temporal lobe memory subsystems. *Hippocampus* **10**: 475–482.
- Manns, J. R., and Squire, L. R. 1999. Impaired recognition memory on the doors and people test after damage limited to the hippocampal region. *Hippocampus* **9**: 495–499.

- Martin, R. C., Meador, K. J., Loring, D. W., Bowers, D., and Heilman, K. M. 1990. The contribution of an imagery code to verbal memory. *Cortex* **26**: 443–450.
- Masuo, O., Maeshima, S., Kubo, K., Terada, T., Nakai, K., Itakura, T., and Komai, N. 1999. A case of amnesic syndrome caused by a subcortical haematoma in the right occipital lobe. *Brain Inj.* **13**: 213–216.
- Milner, A. D., Dijkerman, H. C., and Carey, D. P. 1999. Visuospatial processing in a case of visual form agnosia. In *The Hippocampal and Parietal Foundations of Spatial Cognition* (N. Burgess, K. J. Jeffery, and J. O'Keefe, Eds.), pp. 443–466. Oxford Univ. Press, Oxford.
- Milner, B., Petrides, M., and Smith, M. L. 1985. Frontal lobes and the temporal organization of memory. *Hum. Neurobiol.* **4**: 137–142.
- Morris, R., Petrides, M., and Pandya, D. N. 1999. Architecture and connections of retrosplenial area 30 in the rhesus monkey (*Macaca mulatta*). *Eur. J. Neurosci.* **11**: 2506–2518.
- Morris, R. G., Garrud, P., Rawlins, J. N., and O'Keefe, J. 1982. Place navigation impaired in rats with hippocampal lesions. *Nature* **297**: 681–683.
- Moscovitch, C., Kapur, S., Kohler, S., and Houle, S. 1995. Distinct neural correlates of visual long-term memory for spatial location and object identity: A positron emission tomography study in humans. *Proc. Natl. Acad. Sci. USA* **92**: 3721–3725.
- Moscovitch, M. 1995. Models of consciousness and memory. In *The Cognitive Neurosciences* (M. Gazzaniga, Ed.), pp. 1341–1356. MIT Press, Cambridge, MA.
- Moscovitch, M., and Melo, B. 1997. Strategic retrieval and the frontal lobes: Evidence from confabulation and amnesia. *Neuropsychologia* **35**: 1017–1034.
- Mountcastle, V. B., Lynch, J. C., Georgopoulos, A., Sakata, H., and Acuna, C. 1975. Posterior parietal association cortex of the monkey: Command functions for operations within extrapersonal space. *J. Neurophysiol.* **38**: 871–908.
- Murray, E. A., and Mishkin, M. 1998. Object recognition and location memory in monkeys with excitotoxic lesions of the amygdala and hippocampus. *J. Neurosci.* **18**: 6568–6582.
- Nunn, J. A., Graydon, F. J., Polkey, C. E., and Morris, R. G. 1999. Differential spatial memory impairment after right temporal lobectomy demonstrated using temporal titration. *Brain* **122**: 47–59.
- Nyberg, L., McIntosh, A. R., Cabeza, R., Habib, R., Houle, S., and Tulving, E. 1996. General and specific brain regions involved in encoding and retrieval of events: What, where, and when. *Proc. Natl. Acad. Sci. USA* **93**: 11280–11285.
- O'Keefe, J., and Nadel, L. 1978. *The Hippocampus as a Cognitive Map*. Oxford Univ. Press.
- Opitz, B., Mecklinger, A., Friederici, A. D., and von Cramon, D. Y. 1999. The functional neuroanatomy of novelty processing: Integrating ERP and fMRI results. *Cereb. Cortex* **9**: 379–391.
- Owen, A. M., Morris, R. G., Sahakian, B. J., Polkey, C. E., and Robbins, T. W. 1996. Double dissociations of memory and executive functions in working memory tasks following frontal lobe excisions, temporal lobe excisions or amygdalo-hippocampectomy in man. *Brain* **119**: 1597–1615.
- Pigott, S., and Milner, B. 1993. Memory for different aspects of complex visual scenes after unilateral temp. *Neuropsychologia* **31**: 1–15.
- Postle, B. R., Stern, C. E., Rosen, B. R., and Corkin, S. 2000. An fMRI investigation of cortical contributions to spatial and nonspatial visual working memory. *NeuroImage* **11**: 409–423.
- Rolls, E. T., Robertson, R. G., and Georges-Francois, P. 1997. Spatial view cells in the primate hippocampus. *Eur. J. Neurosci.* **9**: 1789–1794.
- Rugg, M. D., Fletcher, P. C., Chua, P. M., and Dolan, R. J. 1999. The role of the prefrontal cortex in recognition memory and memory for source: An fMRI study. *NeuroImage* **10**: 520–529.
- Rugg, M. D., Fletcher, P. C., Frith, C. D., Frackowiak, R. S., and Dolan, R. J. 1996. Differential activation of the prefrontal cortex in successful and unsuccessful memory retrieval. *Brain* **119**: 2073–2083.
- Schacter, D. L., and Wagner, A. D. 1999a. Medial temporal lobe activations in fMRI and PET studies of episodic encoding and retrieval. *Hippocampus* **9**: 7–24.
- Scoville, W. B., and Milner, B. 1957. Loss of recent memory after bilateral hippocampal lesions. *J. Neurol. Neurosurg. Psychiatry* **20**: 11–21.
- Smith, M. L., Leonard, G., Crane, J., and Milner, B. 1995. The effects of frontal- or temporal-lobe lesions on susceptibility to interference in spatial memory. *Neuropsychologia* **33**: 275–285.
- Smith, M. L., and Milner, B. 1981. The role of the right hippocampus in the recall of spatial location. *Neuropsychologia* **19**: 781–793.
- Smith, M. L., and Milner, B. 1989. Right hippocampal impairment in the recall of spatial location: Encoding deficit or rapid forgetting? *Neuropsychologia* **27**: 71–81.
- Snyder, L. H., Grieve, K. L., Brotchie, P., and Andersen, R. A. 1998. Separate body- and world-referenced representations of visual space in parietal cortex. *Nature* **394**: 887–891.
- Spies, H. J., Burgess, N., Hartley, T., Vargha-Khadem, F., and O'Keefe, J. 2001. Bilateral hippocampal pathology impairs topographical and episodic memory but not visual pattern matching. *Hippocampus*, in press.
- Takahashi, N., Kawamura, M., Shiota, J., Kasahata, N., and Hirayama, K. 1997. Pure topographic disorientation due to right retrosplenial lesion. *Neurology* **49**: 464–469.
- Taube, J. S. 1998. Head direction cells and the neuropsychological basis for a sense of direction. *Prog. Neurobiol.* **55**: 225–256.
- Tulving, E. 1983. *Elements of Episodic Memory*. Clarendon Press, Oxford.
- Tulving, E. 1993. What is episodic memory? 2: 67–70. *Curr. Perspect. Psychol. Sci.* **2**: 67–70.
- Tulving, E., Kapur, S., Craik, F. I., Moscovitch, M., and Houle, S. 1994. Hemispheric encoding/retrieval asymmetry in episodic memory: Positron emission tomography findings. *Proc. Natl. Acad. Sci. USA* **91**: 2016–2020.
- Ungerleider, L. G. 1995. Functional brain imaging studies of cortical mechanisms for memory. *Science* **270**: 769–775.
- Valenstein, E., Bowers, D., Verfaellie, M., Heilman, K. M., Day, A., and Watson, R. T. 1987. Retrosplenial amnesia. *Brain* **110**: 1631–1646.
- Vargha-Khadem, F., Gadian, D. G., Watkins, K. E., Connelly, A., Van Paesschen, W., and Mishkin, M. 1997. Differential effects of early hippocampal pathology on episodic and semantic memory. *Science* **277**: 376–380.
- Wan, H., Aggleton, J. P., and Brown, M. W. 1999. Different contributions of the hippocampus and perirhinal cortex to recognition memory. *J. Neurosci.* **19**: 1142–1148.
- Warrington, E. K., and Weiskrantz, L. 1982. Amnesia: A disconnection syndrome? *Neuropsychologia* **20**: 233–248.
- Wiggs, C. L., Weisberg, J., and Martin, A. 1999. Neural correlates of semantic and episodic memory retrieval. *Neuropsychologia* **37**: 103–118.
- Zhu, X. O., McCabe, B. J., Aggleton, J. P., and Brown, M. W. 1996. Mapping visual recognition memory through expression of the immediate early gene *c-fos*. *Neuroreport* **7**: 1871–1875.
- Zola, S. M., Squire, L. R., Teng, E., Stefanacci, L., Buffalo, E. A., and Clark, R. E. 2000. Impaired recognition memory in monkeys after damage limited to the hippocampal region. *J. Neurosci.* **20**: 451–463.